

# GENERAL DENTISTRY & COMPREHENSIVE CARE

## *Case Studies Volume 1*



*375 East Main Street  
East Islip, NY 11730  
631-581-5121  
[www.drforlano.com](http://www.drforlano.com)*

DF

---

**Thank you** for considering us for your general dental needs.

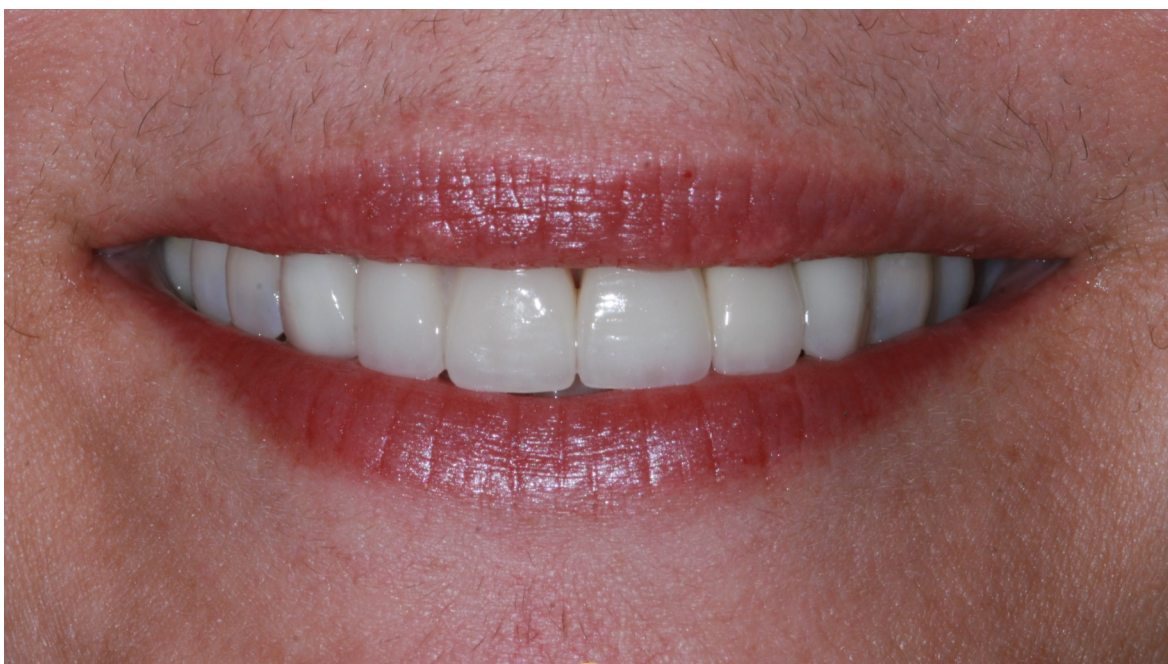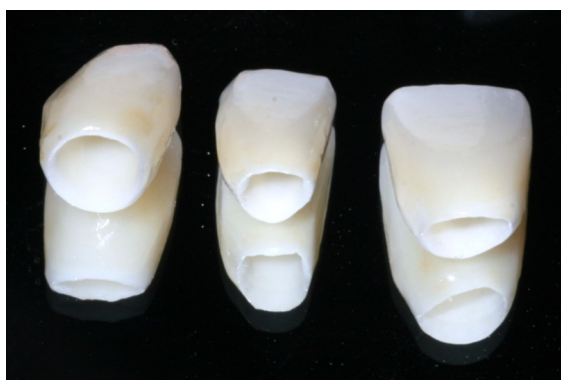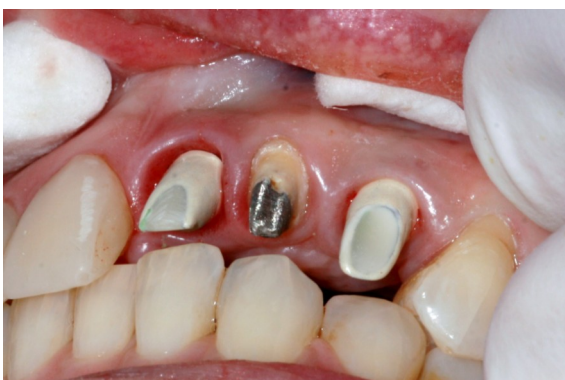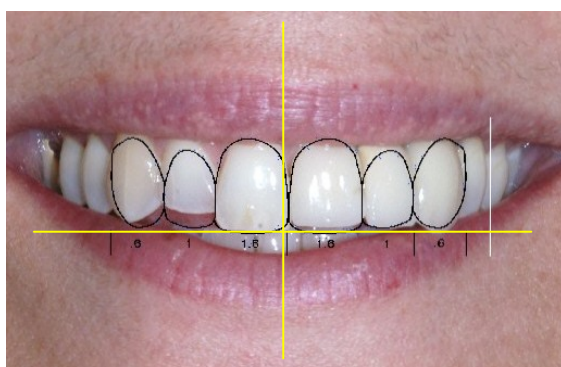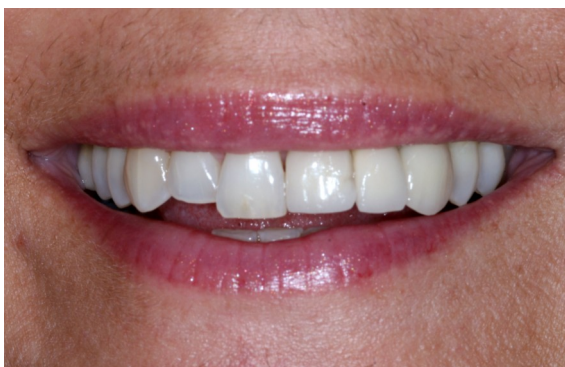All phases of general dentistry are available here in our office. We treat patients of all ages. Our services range from preventive care, fillings and crowns,...to one-visit root canal therapy, minor oral surgery, implants and orthodontics.

For complete rehabilitation cases, we offer several restorative and prosthetic options. Whatever your needs, we can assure precise and comfortable treatment for you and your family.

*Dr. David Forlano*

---

# Porcelain Crowns

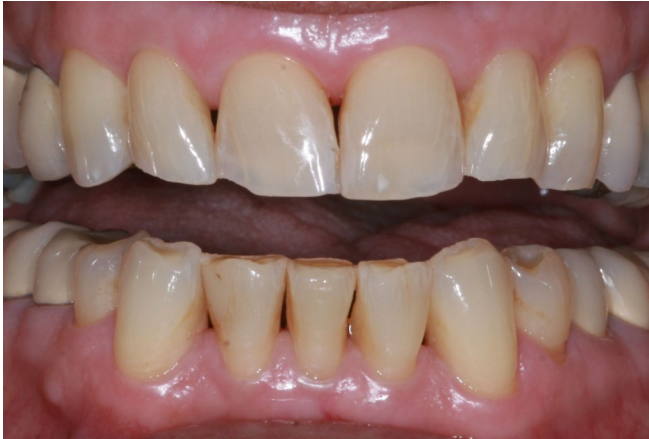

  
**Dr. David Forlano**  
Elevating Your Expectations

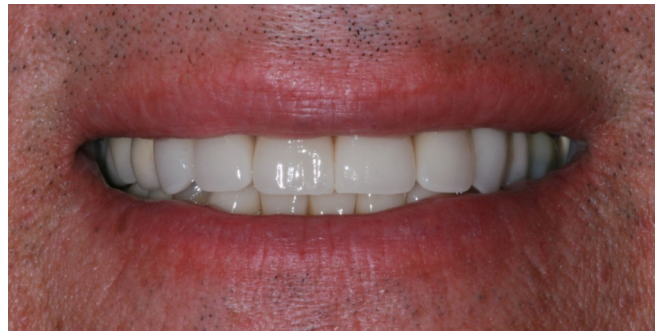
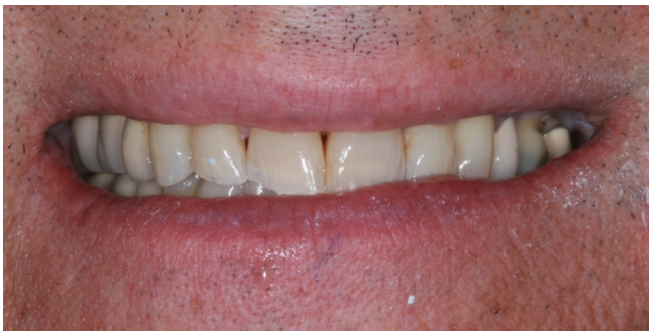
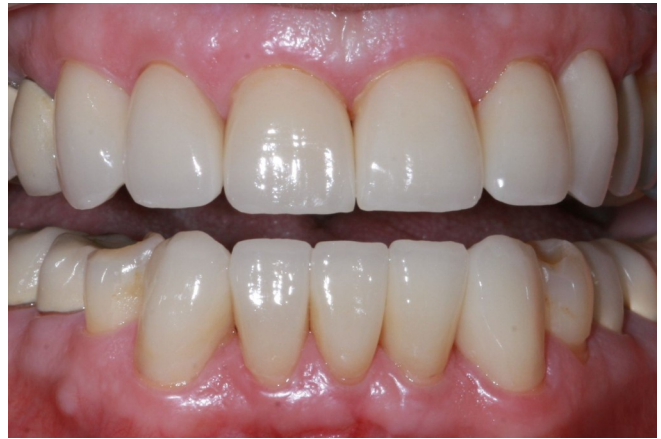# Porcelain Crowns

*Before*



*After*



The upper and lower incisors exhibited a classic case of dental attrition. Dental attrition is a type of tooth wear usually caused by bruxism, or abnormal tooth-to-tooth contact. Bruxism is clenching and grinding of the teeth and results in loss of enamel and dentin. In this case, the enamel is completely worn leaving the underlying dentin susceptible to tooth decay and sensitivity.

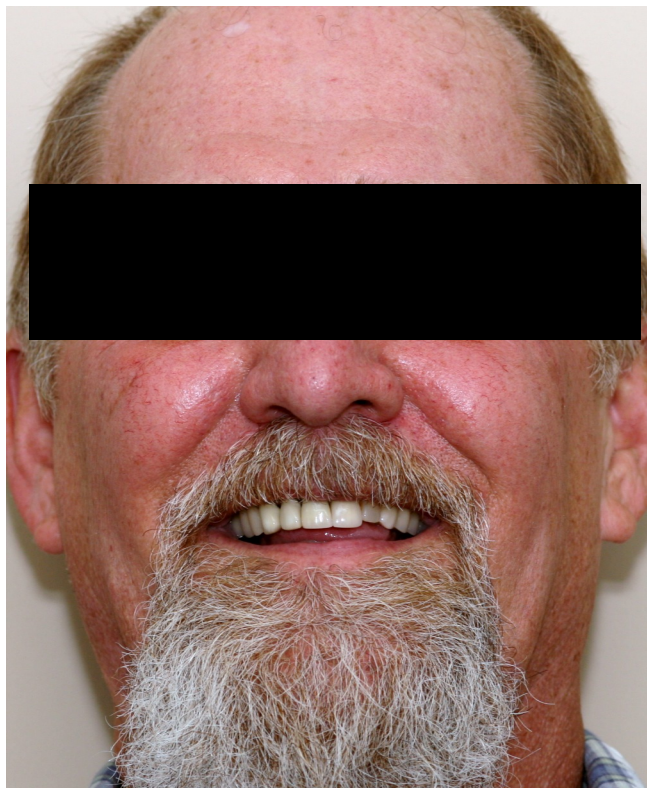The upper and lower incisors and cupsids were restored with lithium disilicate restorations. Lithium disilicate is a glass ceramic that has optimized translucency, durability, and strength. It is truly a revolution for the dental industry. Never before has a material been able to combine high strength for bruxism and high esthetics for natural beauty.



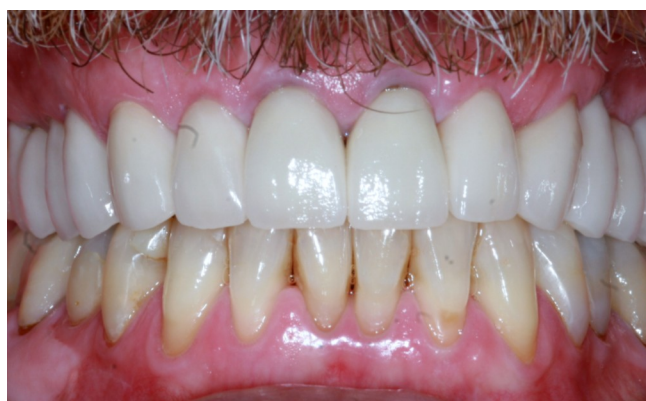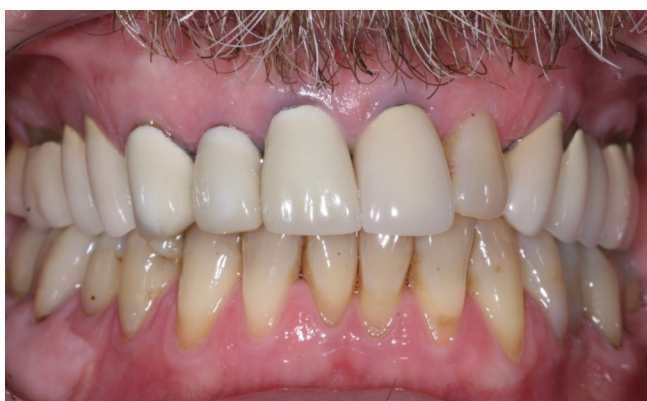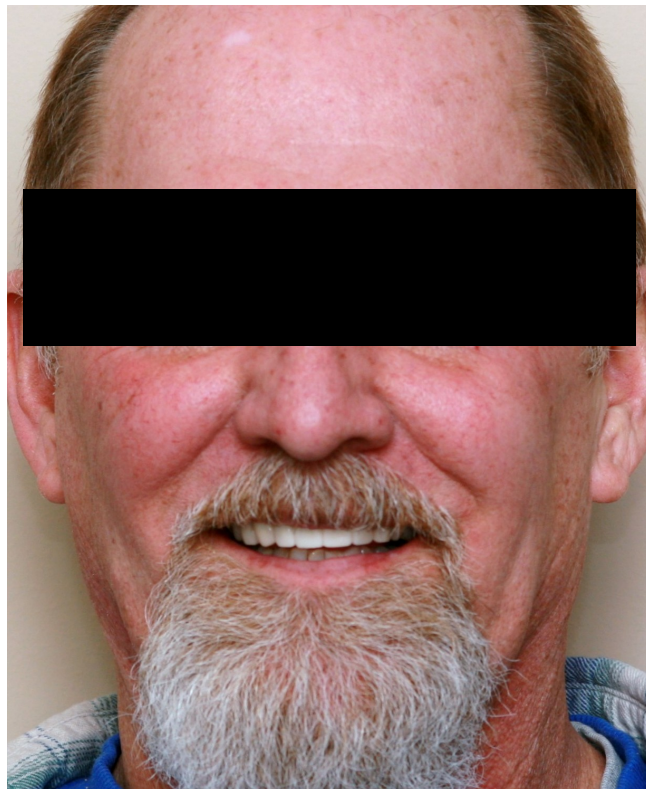# Porcelain Crowns, Uppers

---

*Before*



*After*





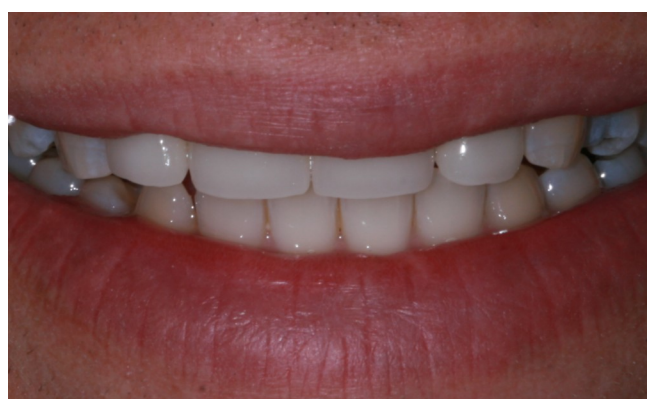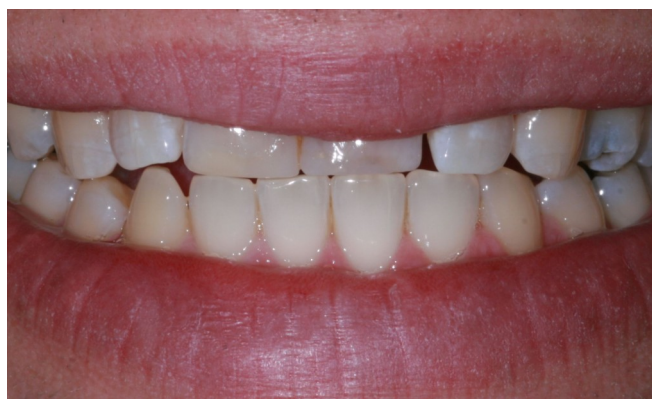# Porcelain Crowns, Uppers

---

*Before*



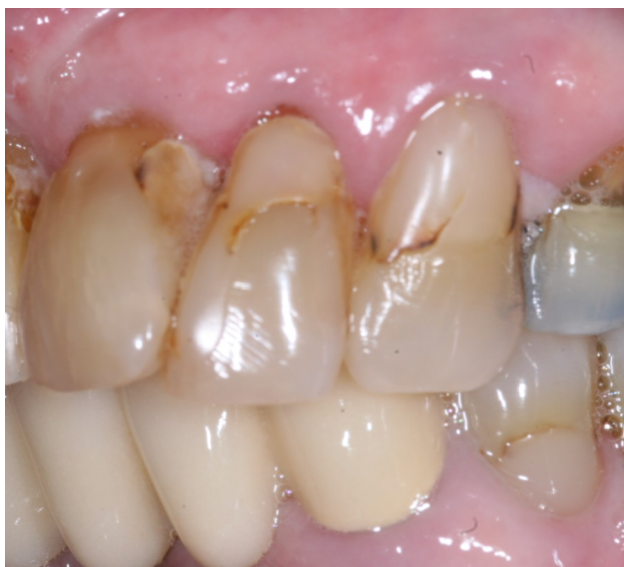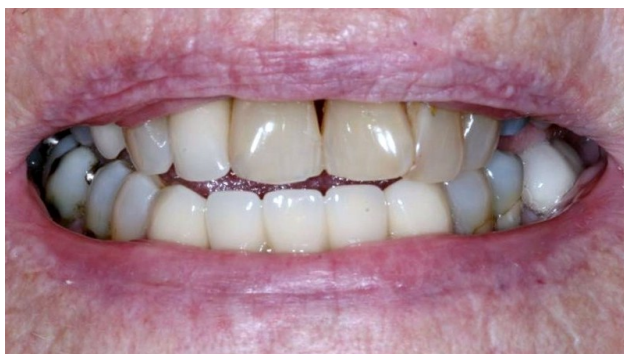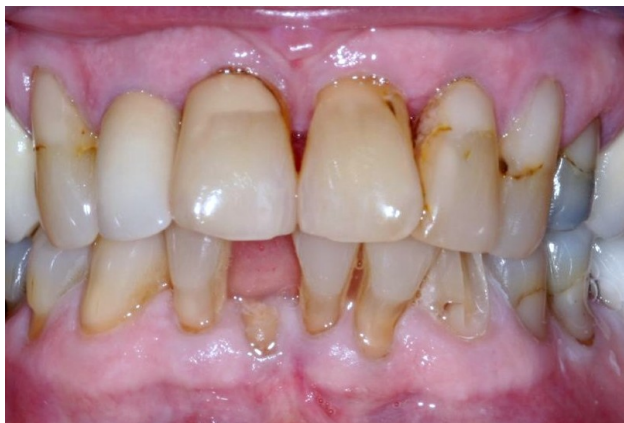*After*



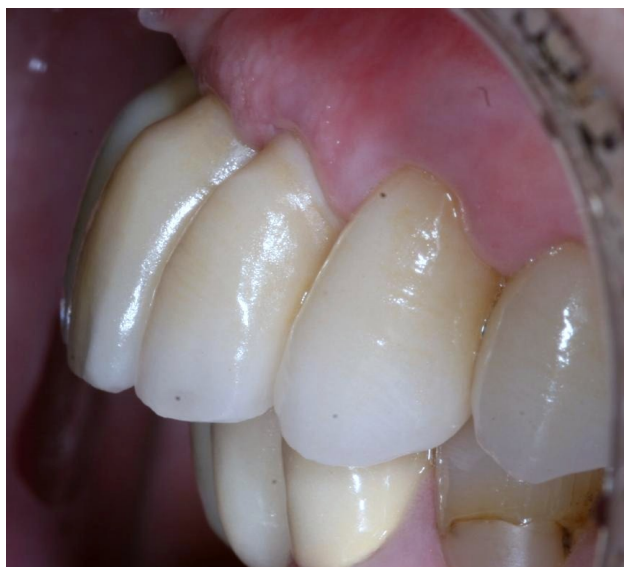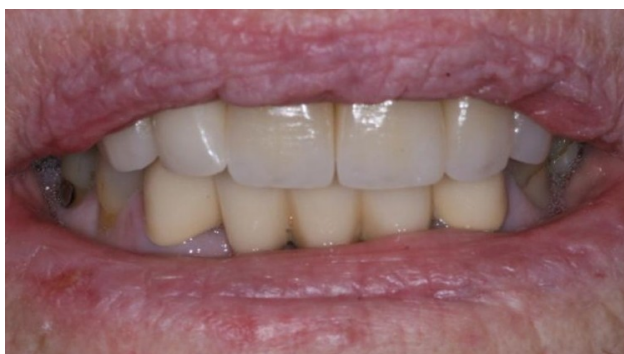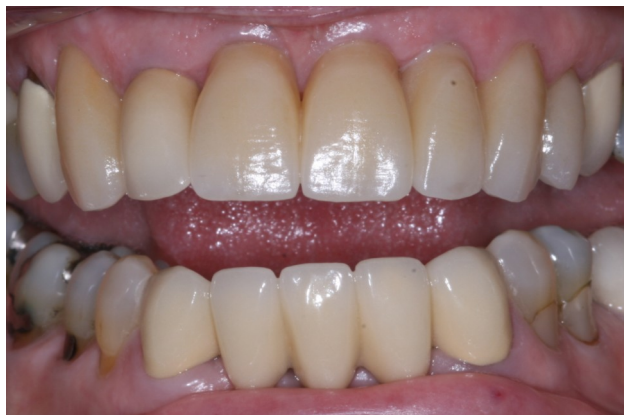  
Dr. David Forlano  
Elevating Your Expectations

# Porcelain Crowns, Geriatric

*Before*



*After*



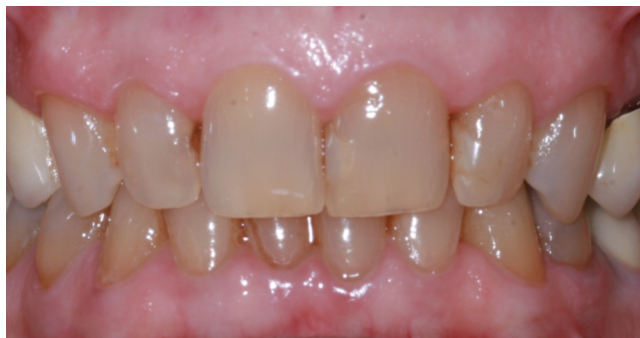Dr. David Forlano  
Elevating Your Expectations



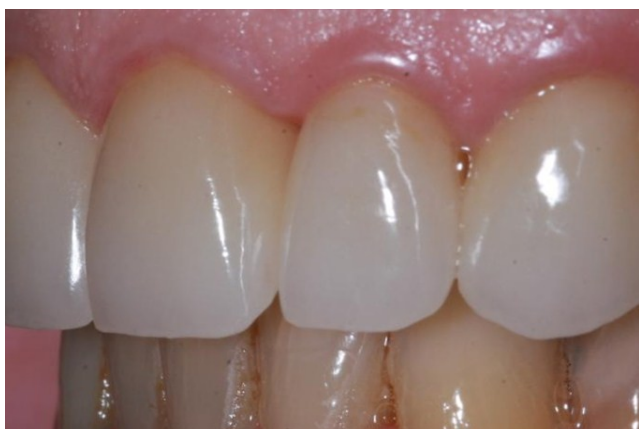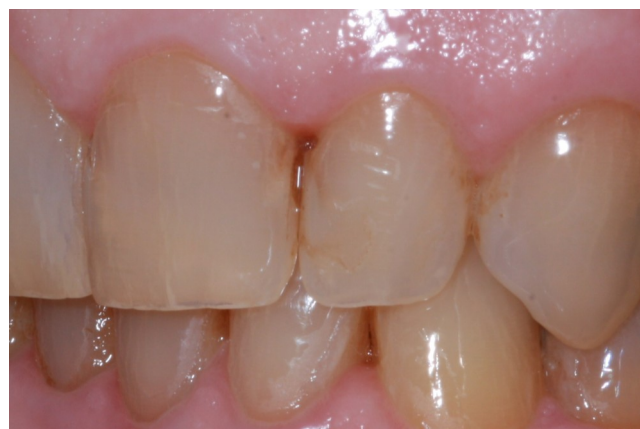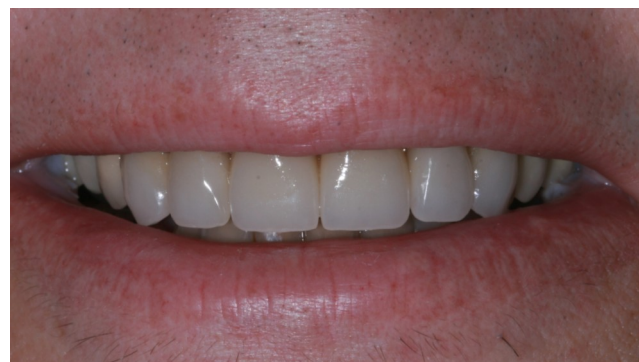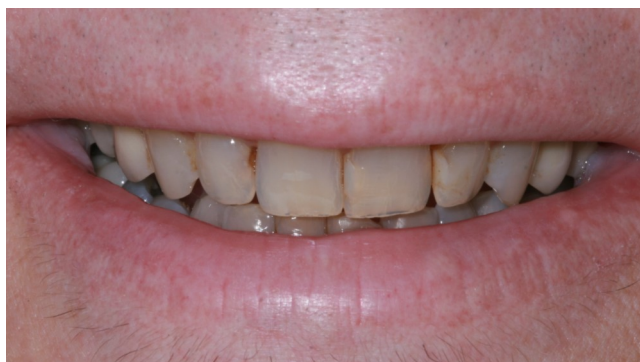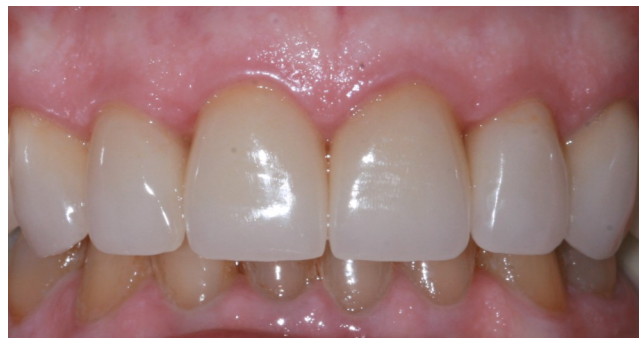# Porcelain Crowns, Geriatric

---

*Before*



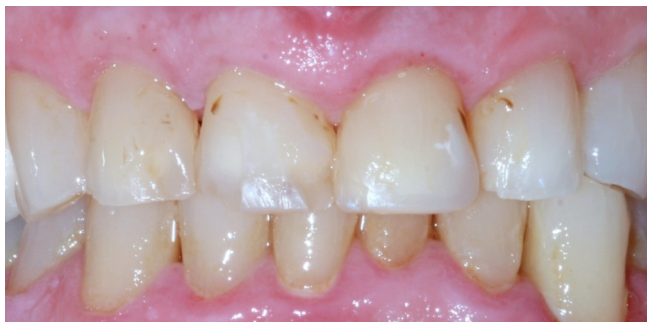*After*



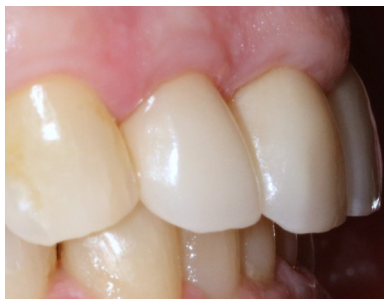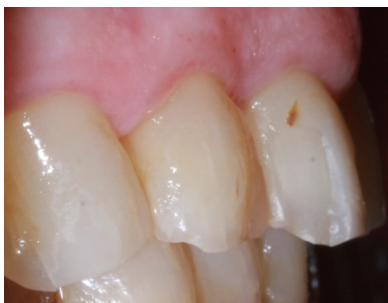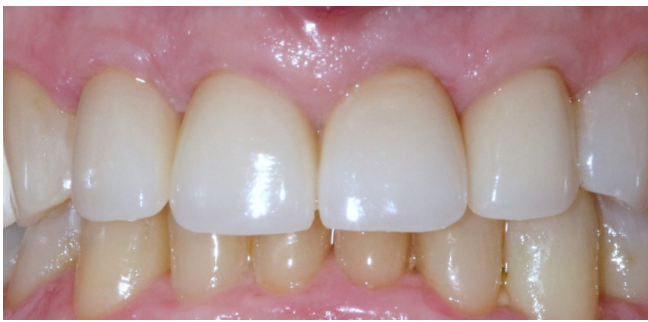  
Dr. David Forlano  
Elevating Your Expectations

# Porcelain Crowns

*Before*



*After*



  
Dr. David Forlano  
Elevating Your Expectations



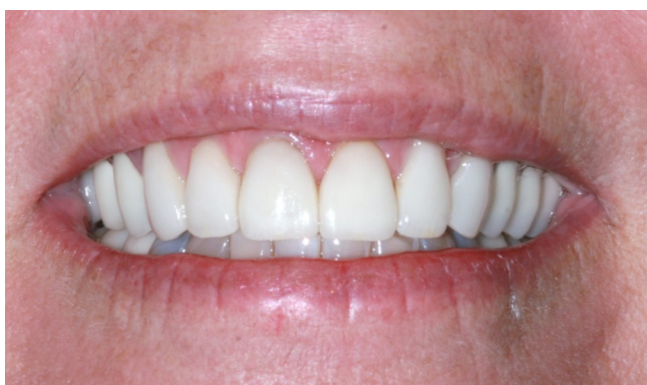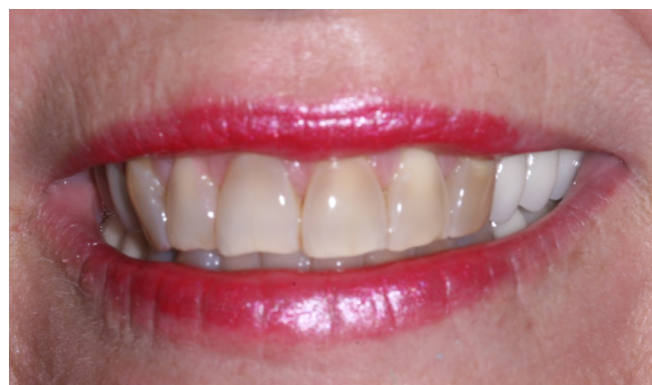# Porcelain Veneers

---

*Before*



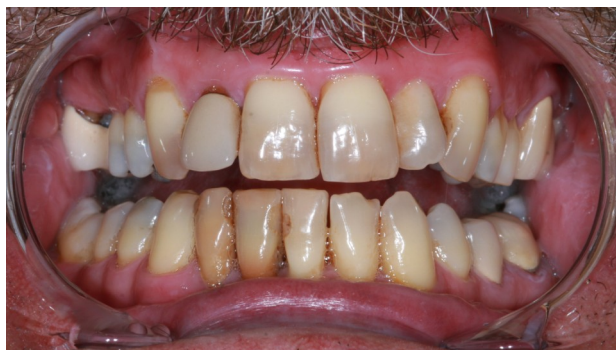*After*



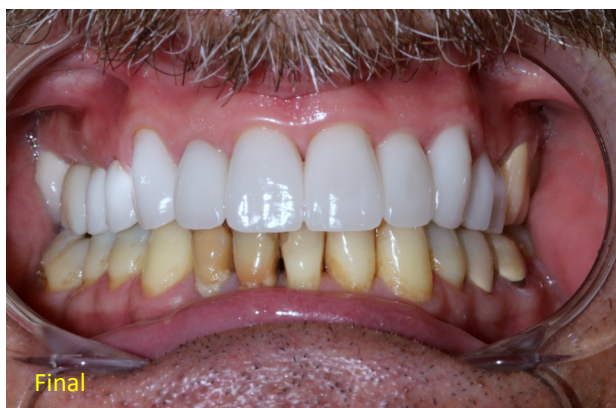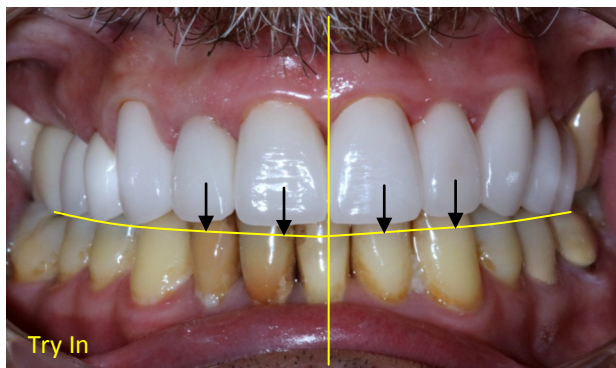
A stylized logo for Dr. David Forlano, featuring a large, elegant, cursive 'D' and 'F' in gold. The text 'Dr. David Forlano' is written in a serif font across the middle of the 'D' and 'F', and 'Elevating Your Expectations' is written in a smaller sans-serif font below it.  
Dr. David Forlano  
Elevating Your Expectations

# Porcelain Crowns

*Before*



*After*

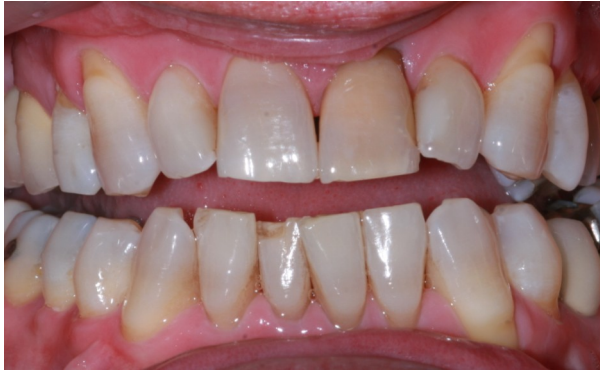

  
Dr. David Forlano  
Elevating Your Expectations

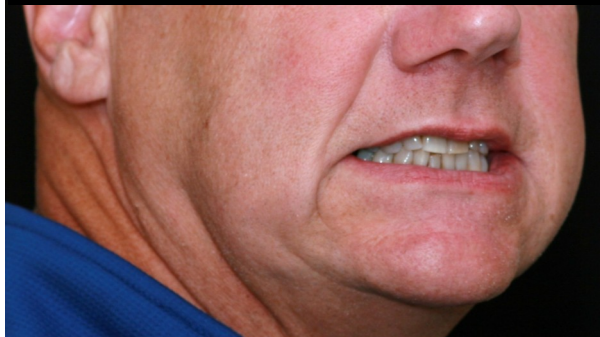
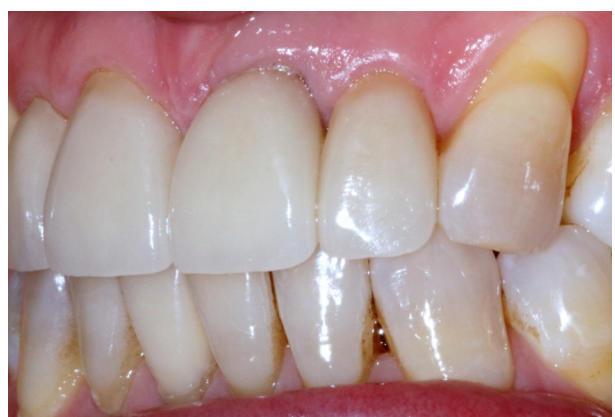
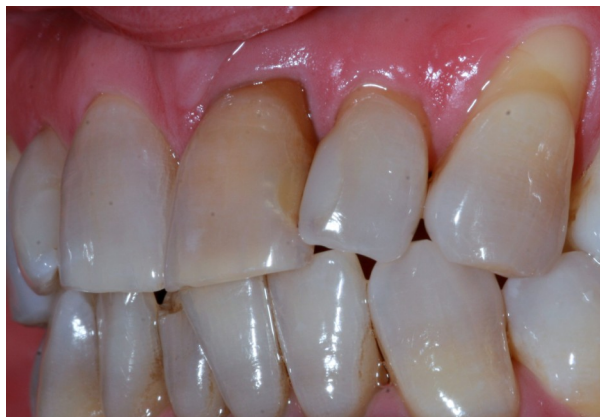
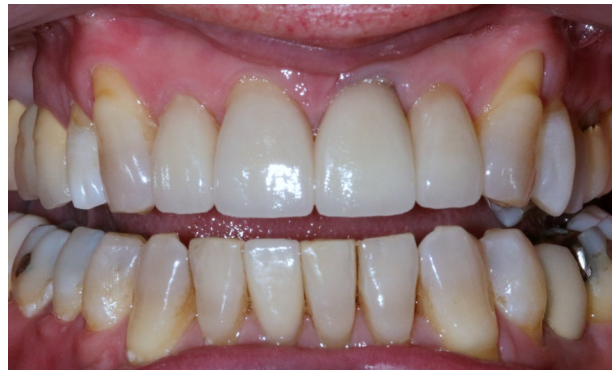

# Invisalign & Porcelain Crowns

*Before*



*After*



Dr. David Forlano  
Elevating Your Expectations

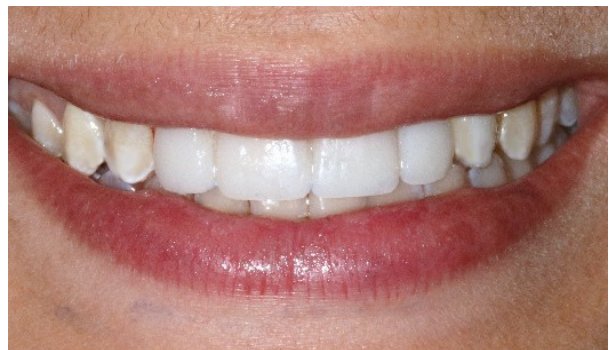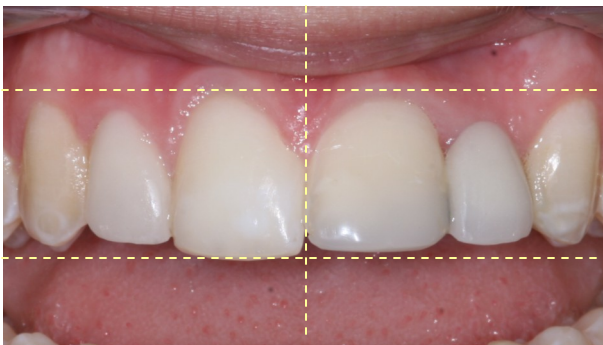# Porcelain Veneers & Dental Implant, Young Adult

---

*Before*



*After*



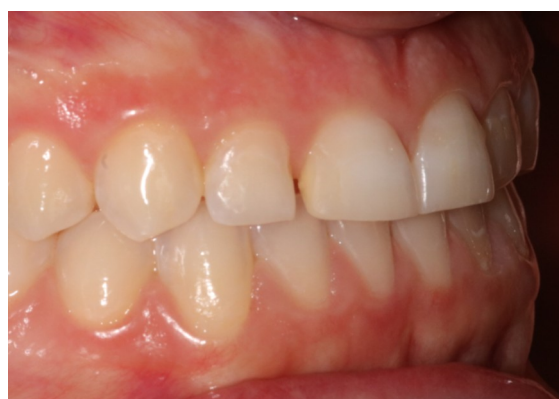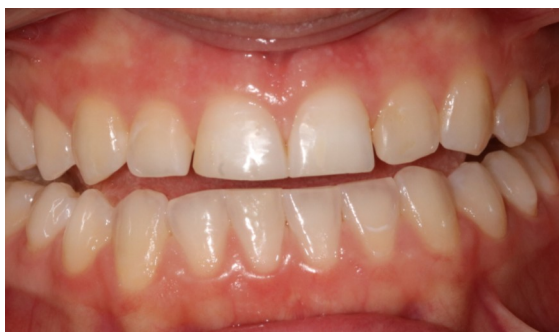  
Dr. David Forlano  
Elevating Your Expectations



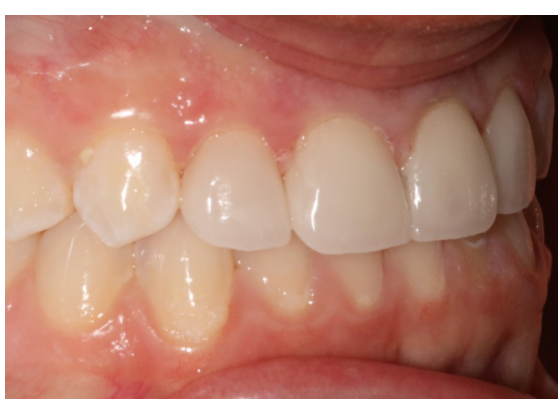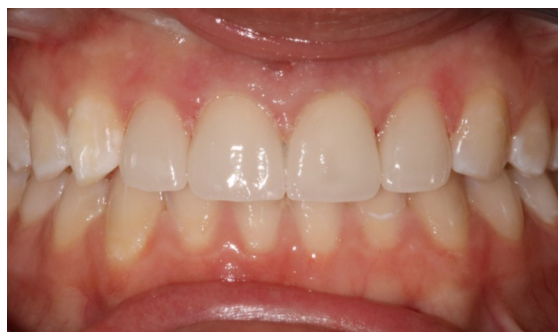# Porcelain Veneers, Young Adult

---

*Before*



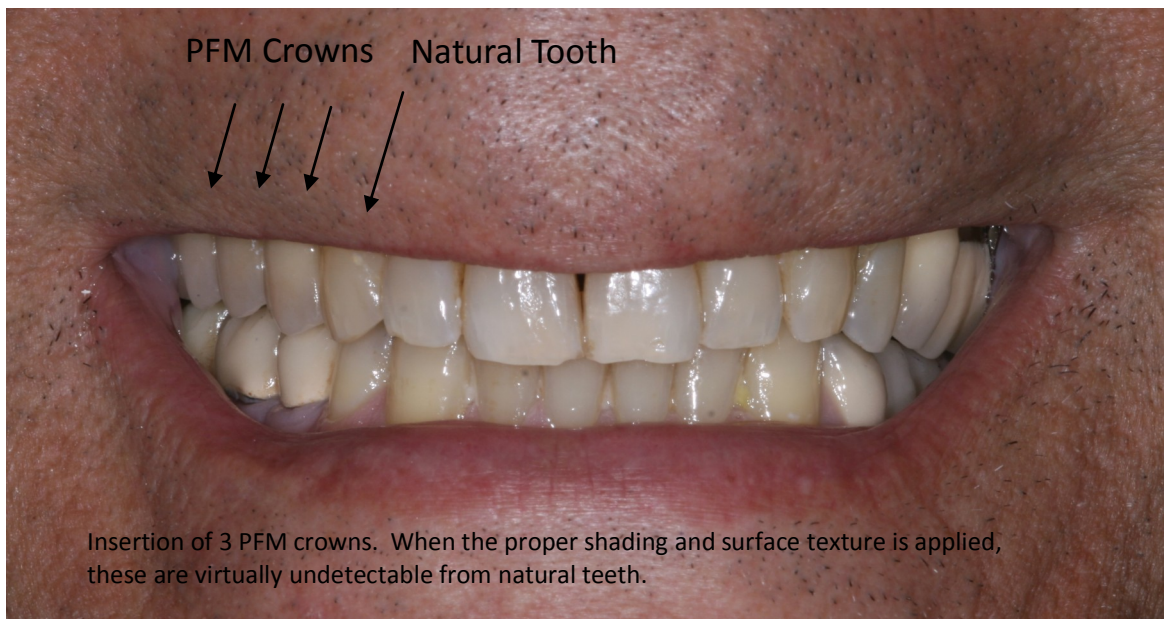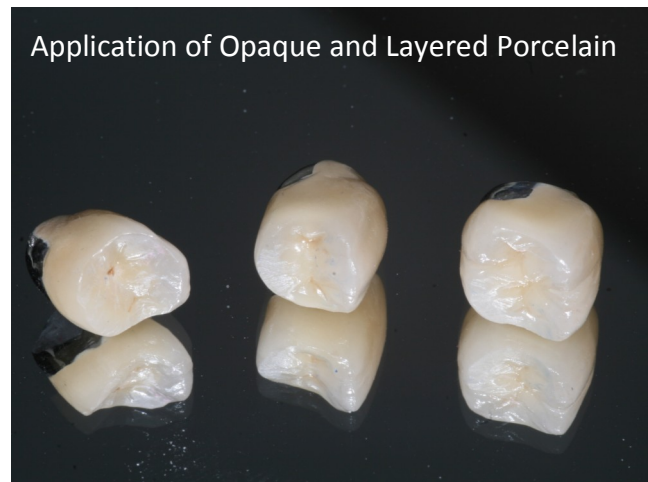
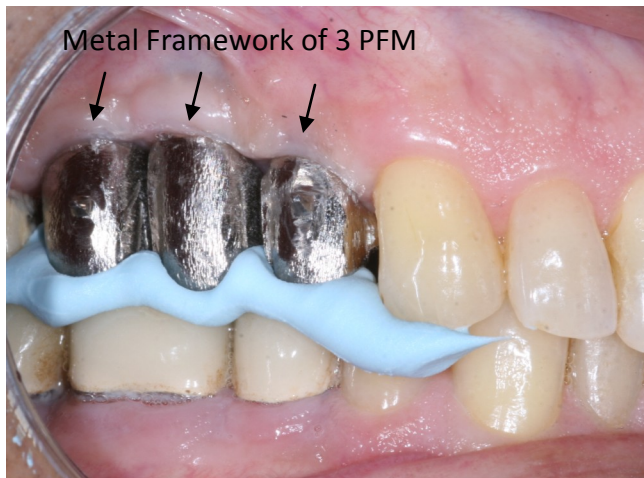
*After*



  
Dr. David Forlano  
Elevating Your Expectations

# Porcelain Fused to Metal Crowns

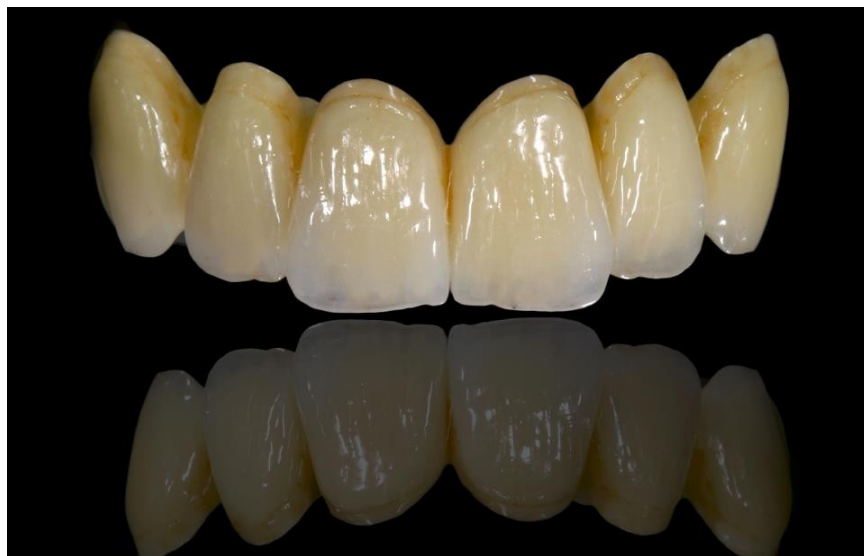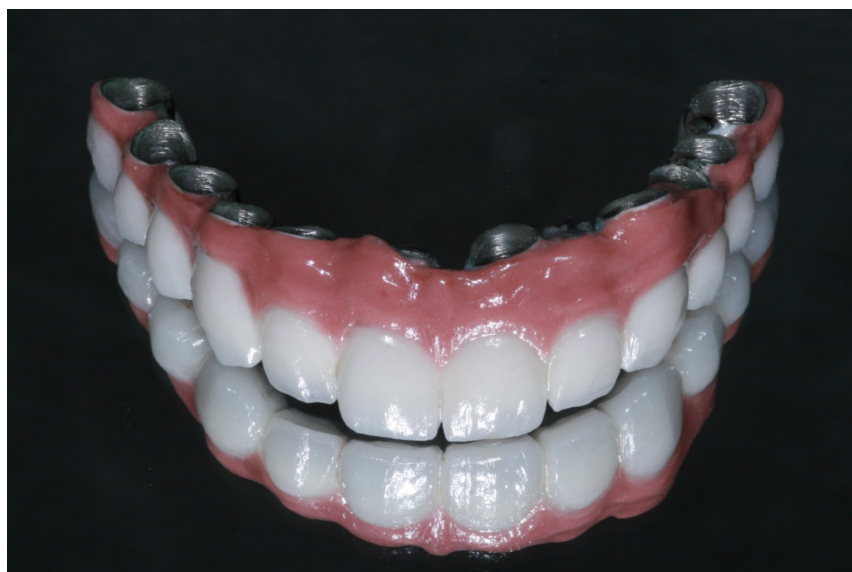*Porcelain fused to metal (PFM) crowns are tried and true, and comprise approximately 80% of the crowns manufactured today. PFM crowns have been considered the gold standard for the repair of damaged teeth. PFM crowns have good mechanical properties, satisfactory esthetic results, and an acceptable biological quality needed for periodontal health. However, PFM crowns have some limitations that may limit their use. For example, the esthetic of PFM crowns is limited by the metal framework and the layer of opaque porcelain needed for masking the underlying metal grayish shade.*





# Porcelain Fused to Metal Bridges

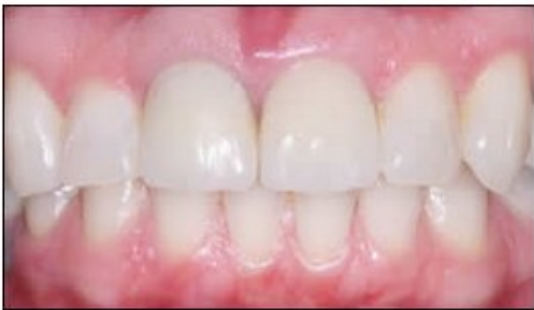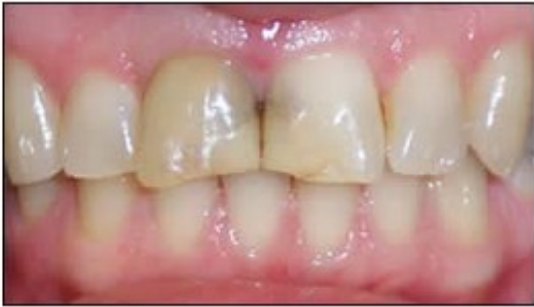*Porcelain fused to metal (PFM) bridges are also tried and true, and have been considered the gold standard for bridging missing teeth. Below are some of our PFM bridges crafted by our talented lab technicians and ceramist*



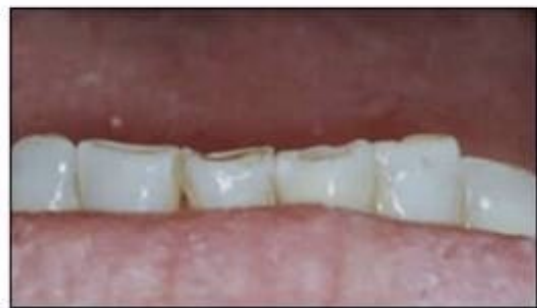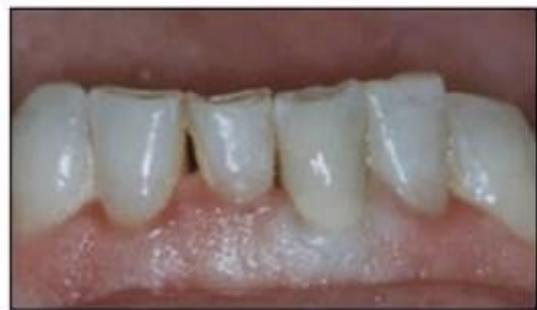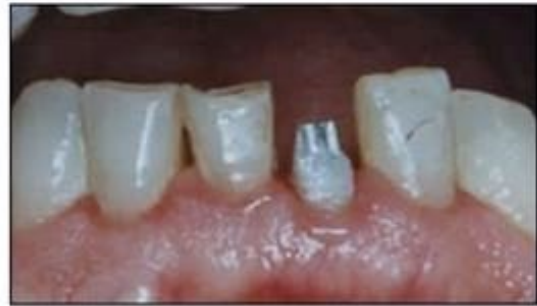# Porcelain Fused to Metal Crowns

---

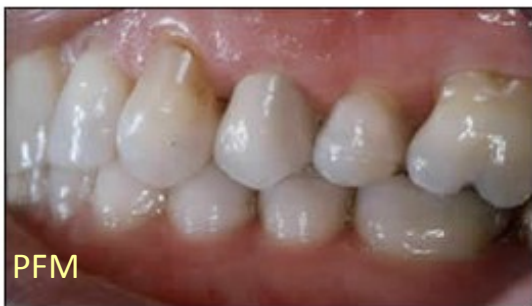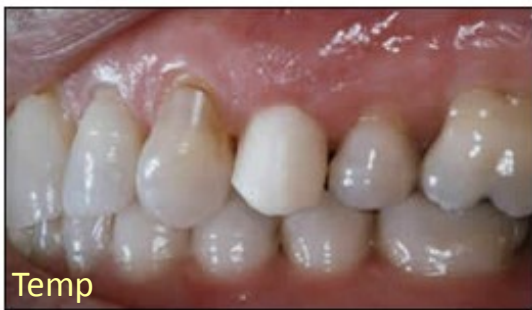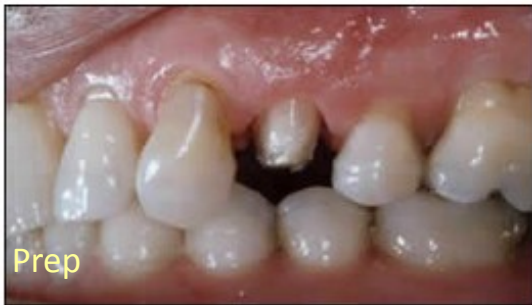*Maxillary Central Incisors*



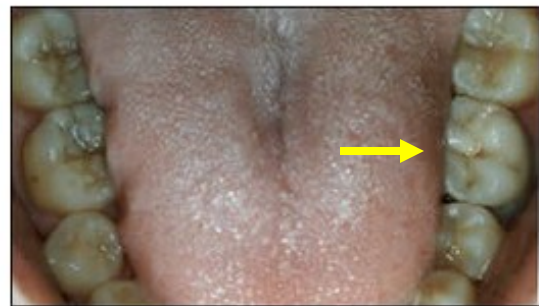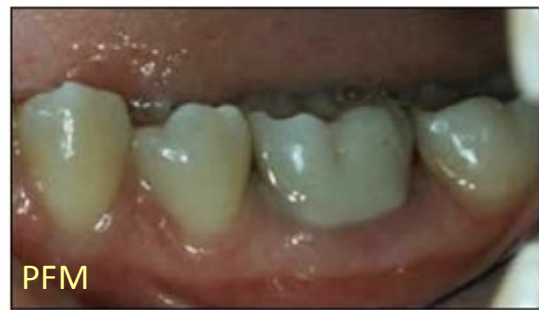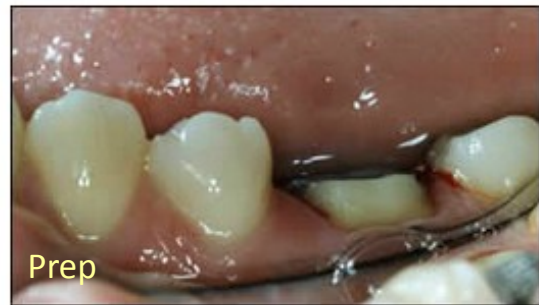*Mandibular Central Incisor*



*Maxillary Bicuspid*



*Mandibular Molar*

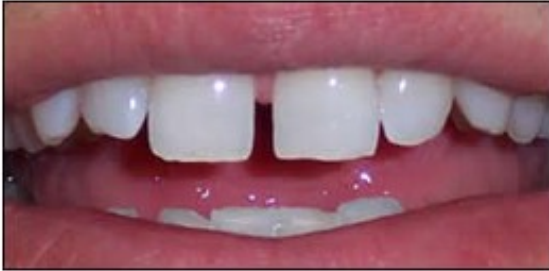

# Bonding: Diastema Closures

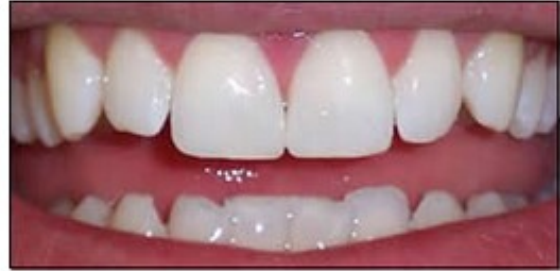*A diastema is a space or gap between two teeth. It may be corrected with orthodontics, porcelain restorations or composite bonding. These three cases were corrected with composite bonding.*

1

*Before*

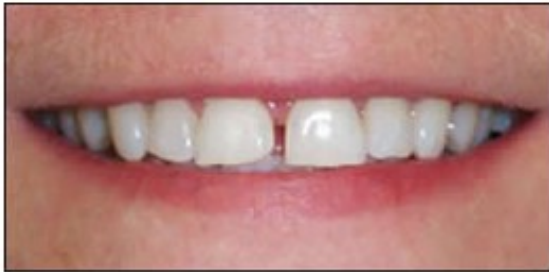

*After*

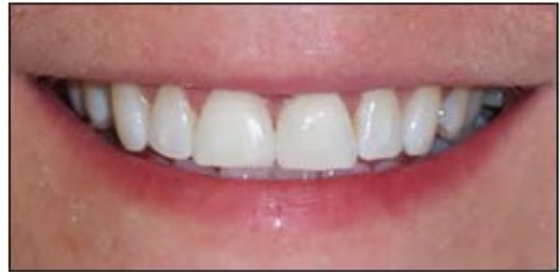

2

*Before*

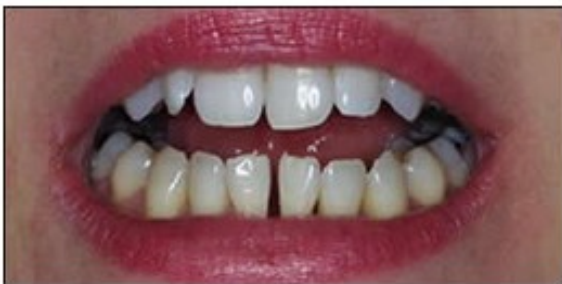

*After*

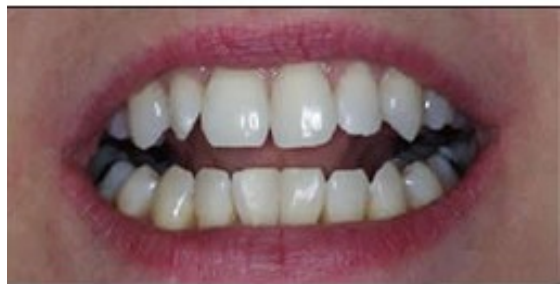

3

*Before*



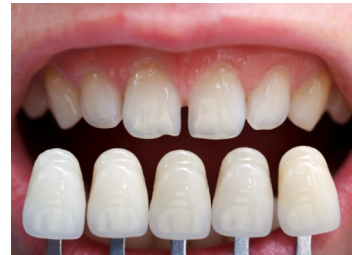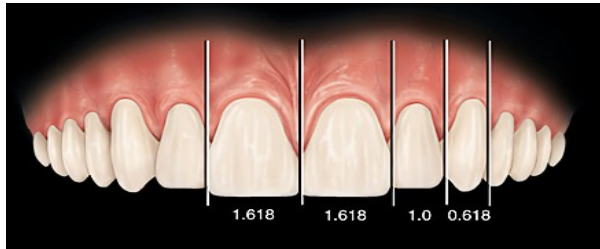
*After*





# Bonding: Chipped Teeth

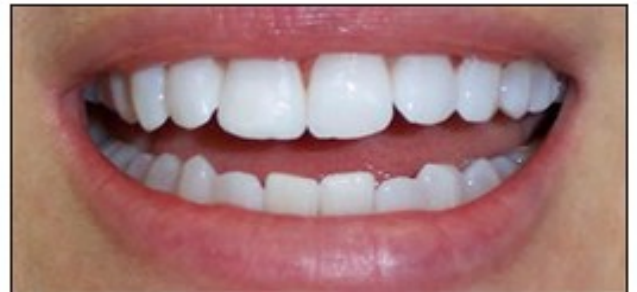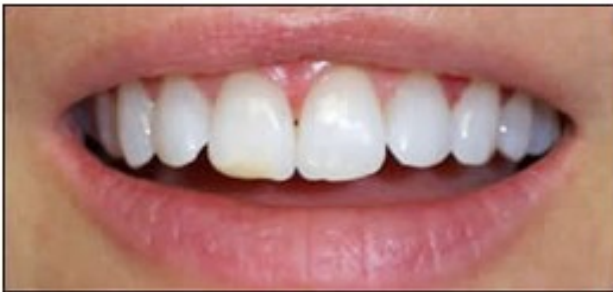*Composite bonding can be utilized to repair chips, fractures and gaps between teeth. Evaluation of tooth size, shape and proportions, as well as proper tooth color and shading make the difference between good results and great results.*



*Before*

*After*

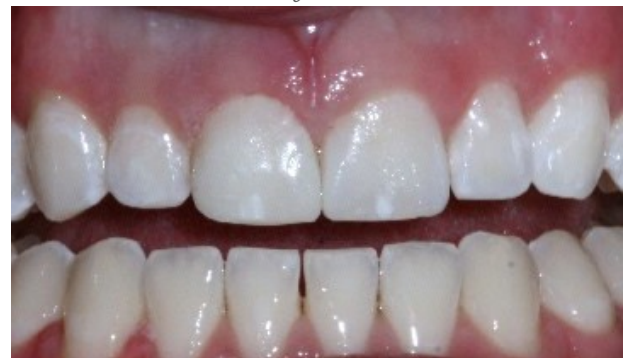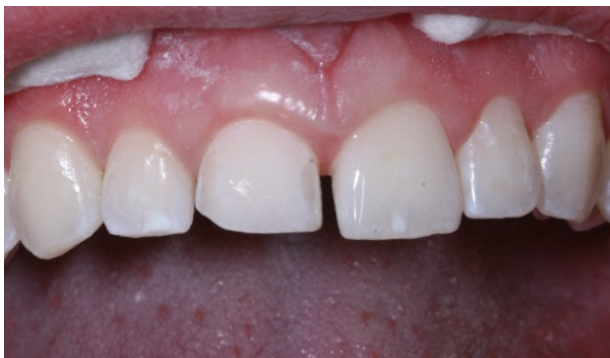1



*Before*

*After*

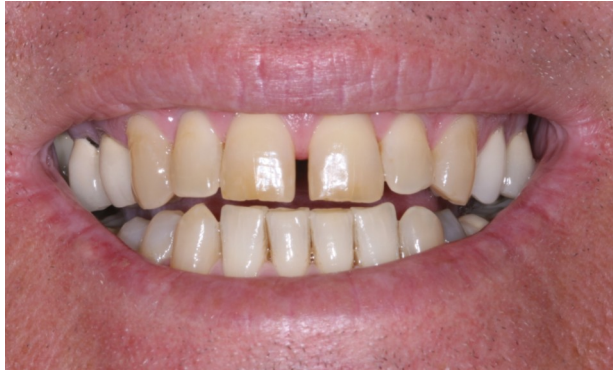2



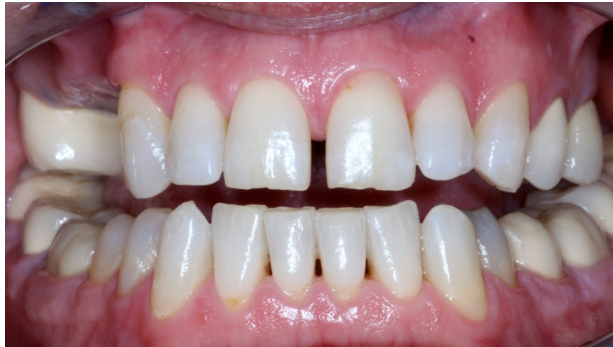  
Dr. David Forlano  
Elevating Your Expectations

# Diastema Closure & Tooth Whitening

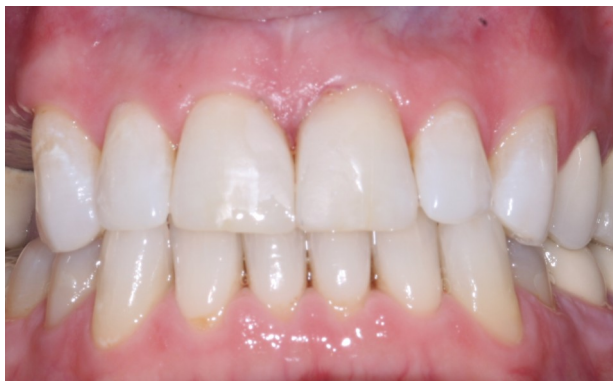
*Before*



*After Tooth Whitening*



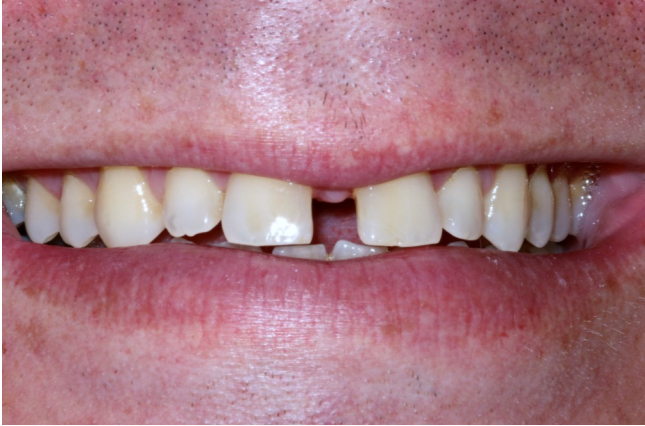*After Diastema Closure*



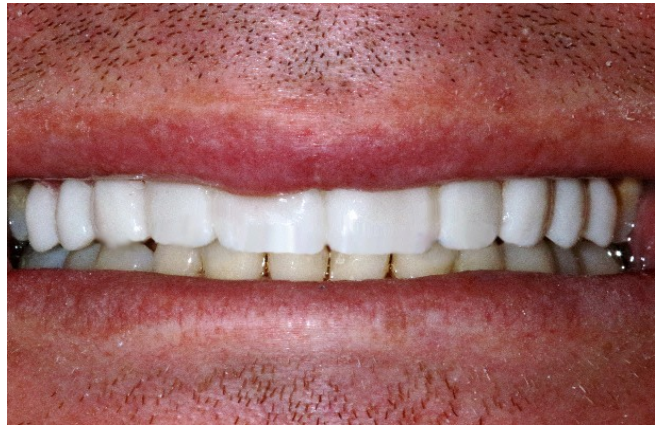

# Diastema Closure & Porcelain Veneers

*Before*



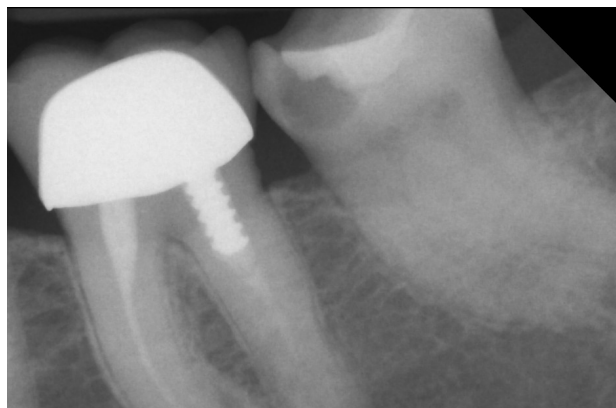*Temps*



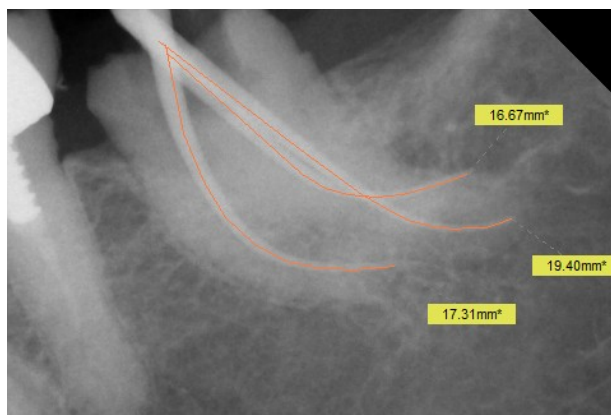
  
Dr. David Forlano  
Elevating Your Expectations

# Root Canal Treatment

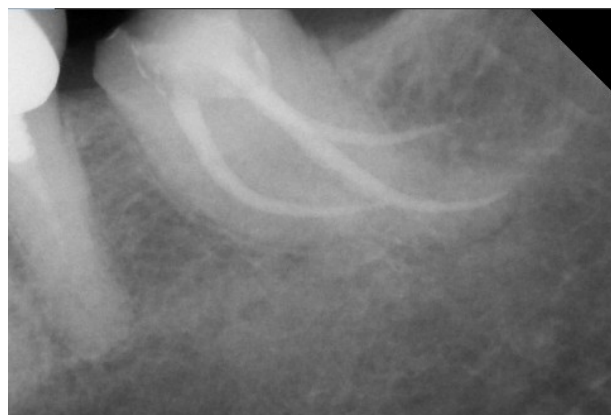Tooth #18 presented with a fracture in close proximity to the pulp chamber which houses the nerves and blood vessels.



The three roots had near 90 degree bends. These roots are ranked among the most difficult to treat. Root perforations or ledging the canals are common problems associated with treating these canals, and if not treated accurately, these problems will render the tooth hopeless and necessitate extraction.



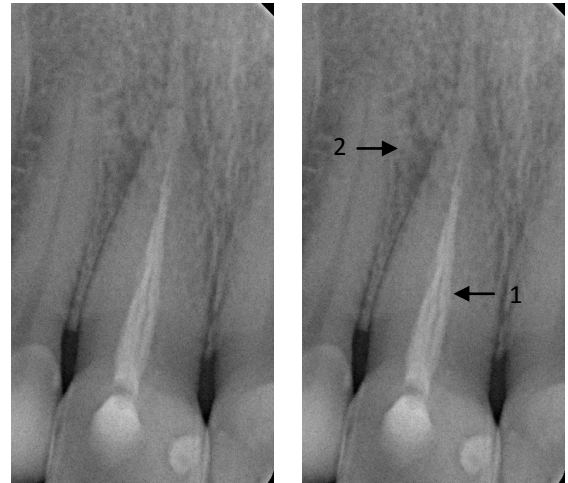
With electronic apex location and nickel-titanium instrumentation, we were able to treat this case precisely and successfully, despite the high level of difficulty.



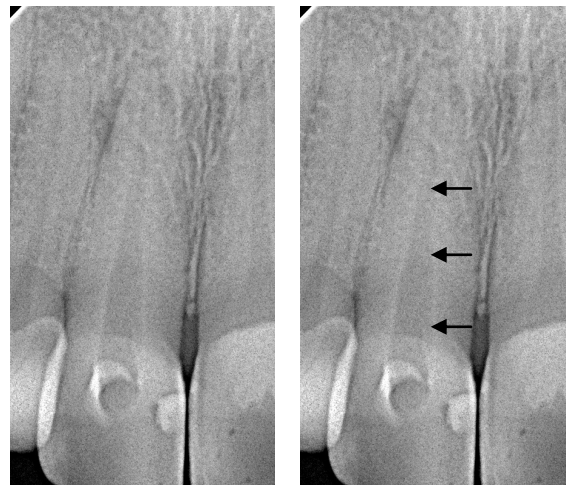
  
Dr. David Forlano  
Elevating Your Expectations

# Root Canal Treatment

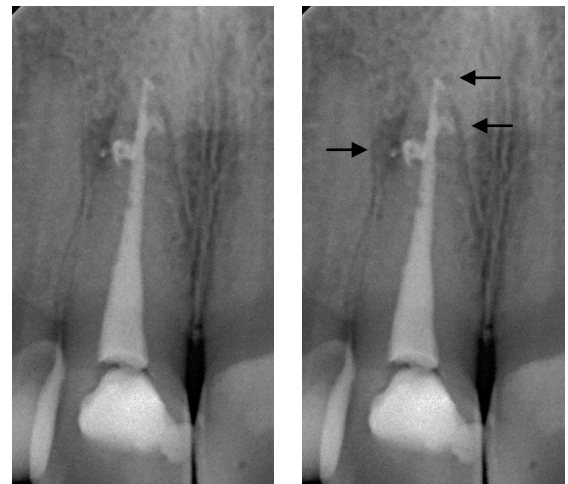
Tooth #8 presented with a failing root canal. Notice the voids<sup>1</sup> within the white root canal filling material and the darker area<sup>2</sup> at the apical third of the root, congruent with the periodontal ligament.



Thorough removal of old root canal filling material is often difficult. Incomplete removal can render the tooth hopeless and necessitate extraction. We were able to remove 100% of the old root canal filling material and locate several accessory canals at the apical third of this tooth. Failure to locate and treat these accessory canals can render the tooth hopeless and necessitate extraction.




We were able to successfully treat the main canal of this tooth, as well as the accessory canals, with a 3-dimension seal. Notice the three portals or “branches” at the apex of the tooth.



  
Dr. David Forlano  
Elevating Your Expectations





Dr. David Forlano is a general dentist trained in rehabilitating the entire masticatory system. The masticatory system is the functioning part of the body responsible for chewing, speaking and swallowing, all controlled by an intricate neuromuscular system.

Dr. Forlano is one of very few dentists to achieve Fellowship awards in three different dental disciplines; General Dentistry through the Academy of General Dentistry, Implantology through the International Congress of Oral Implantologists and Orthodontics through the International Association for Orthodontics. He maintains active membership in these organizations, as well as in the American Academy of Facial Esthetics, the American Dental Association and the Dental Organization for Conscious Sedation. He is a Diplomate of the International Congress of Oral Implantologists.

His diverse experience results in a unique self-contained, multidisciplinary approach to comprehensive dental care.

All of the cases and clinical photographs presented here are of actual patients treated by Dr. David Forlano. Thank you for allowing us to display your cases. Thank you for the opportunity to treat so many interesting cases. I am grateful for your trust & confidence.

DF



*375 East Main Street  
East Islip, NY 11730  
631-581-5121  
[www.drforlano.com](http://www.drforlano.com)*